



**RESENTING CLINICAL SIGNS**

**DATE** History: Recheck DMVD. Receiving pimobendan 2.5 mg am, 1.25 mg pm. Asymptomatic.

4/5/22

**ECHOCARDIOGRAPHIC FINDINGS**

2D, M-mode, and Doppler study. This exam is compared to the one performed 10/7/21.

**PERFORMED BY:**

Dr. Meredith Swart

**INTERPRETED BY**

Keith Blass, DVM,  
MS, DACVIM  
(Cardiology)

There is mild to moderate left atrial dilation. The mitral valve leaflets are thickened and exhibit systolic prolapse. A moderate jet of mitral regurgitation is present. There is mild to moderate left ventricular dilation. Left ventricular systolic function is hyperdynamic. The aorta and aortic valve are normal. Right atrial and right ventricular dimensions are normal. The tricuspid valve is normal. The pulmonary artery and pulmonic valve appear normal, though trace pulmonic insufficiency is present. No pericardial effusion or cardiac masses are seen.

LA - 34.1 mm / prev. 31.9 mm  
LVIDd - 33.8 mm / prev. 32.1 mm  
LVIDs - 17.2 mm / prev. 16.3 mm  
FS - 49% / prev. 49%  
LVOT - 1.45 m/s / prev. 1.36 m/s  
RVOT - 0.91 m/s / prev. 0.89 m/s

**PATIENT**

Tinkerbelle Coelho

**ASSESSMENT/RECOMMENDATIONS**

Normal echocardiogram

**SPECIES**

Canine

This examination demonstrates mild progression of Tinkerbelle's mitral valve disease over the past 6 months, as she now has mild to moderate dilation of both her left atrium and left ventricle. Tinkerbelle's mitral valve disease is still compensated, however, her risk for the development of clinical signs, such as exercise intolerance, syncope, and labored breathing, has increased mildly, therefore, careful monitoring for these signs is recommended.

**BREED**

Terrier Mix

No additional therapy has been proven to be beneficial at this stage of disease, therefore, no additional therapy is recommended at this time.

**SEX**

A recheck echocardiogram is recommended in 6-9 months. Thoracic radiographs are recommended if Tinkerbelle experiences difficulty breathing.

FS

**AGE**

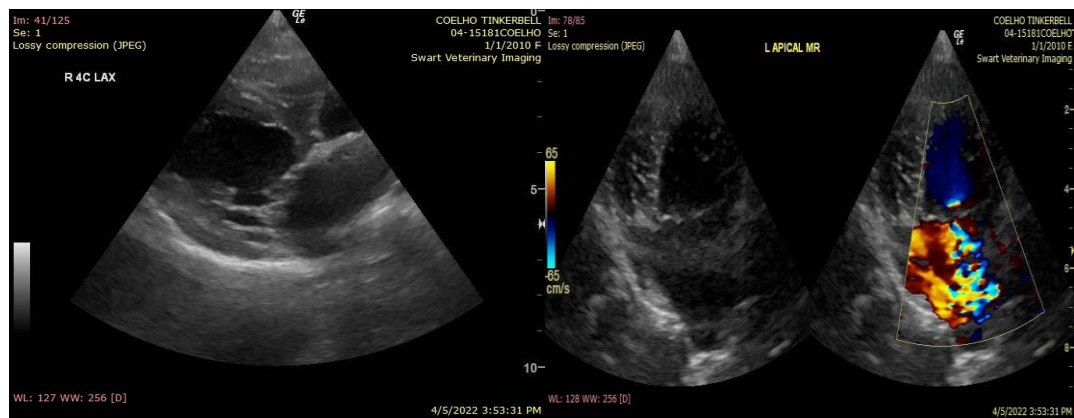
12 y

**WEIGHT**

17 lb

**HOSPITAL NAME**

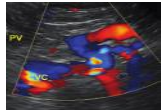
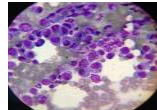
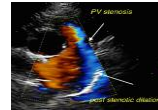
Swart Veterinary  
Imaging



**REFERRING VET**

Dr. Swart

The information and recommendations provided are based on the images presented by the



**DATE** referring veterinarian. No evaluation can be communicated regarding pathology that was not visible in the image/video clips provided.

4/5/22 Thank you for this referral. If the clinical or image interpretation does not parallel your findings or if I can be of any further assistance please contact me.

**PERFORMED BY:** Keith Blass, DVM, MS, DACVIM (Cardiology)  
Dr. Meredith Swart KeithBlass@gmail.com  
631-804-5754

**INTERPRETED BY**

Keith Blass, DVM,  
MS, DACVIM  
(Cardiology)

**PATIENT**

Tinkerbelle Coelho

**SPECIES**

Canine

**BREED**

Terrier Mix

**SEX**

FS

**AGE**

12 y

**WEIGHT**

17 lb

**HOSPITAL NAME**

Swart Veterinary  
Imaging

**REFERRING VET**

Dr. Swart